A CANINE MALIGNANT PERIPHERAL NERVE SHEATH TUMOR ARISING FROM SPLEEN

Nguyen Thi Lan[*], Yamaguchi Ryoji[**], Takayuki Suzuki[**], Nguyen Huu Nam[*]

[*] *Department of Microbiology, Infectious diseases and Pathology, Fuculty of Veterinary Medicine, Hanoi University of Agriculture, Vietnam.*

[**] *Department of Veterinary Pathology, Faculty of Agriculture, University of Miyazaki, Miyazaki 889-2192, Japan.*

ABSTRACT

A malignant peripheral nerve sheath tumor was found in a 14-year-old male cross-breed dog. The tumors were located in the liver and spleen. Histologically, the neoplastic spindle-shaped cells were often arranged in interlacing bundles and fascicles with occasional palisading nuclear and whorl formations. The neoplastic cells had spindle to short spindle nuclei with prominent nucleoli and indistinct cell borders. Mitotic figures were frequently observed. The diagnosis was based on the results of histopathology and immunohistochemistry.

Key words: Dog, malignant peripheral nerve sheath tumor, spleen.

1. INTRODUCTION

Cancer is a common and serious disease for human beings. Many pet owners have had or will have a personal experience with cancer in themselves, a family member or a close friend. Cancer is one of the leading causes of death in dogs and cats today. Cancer is a collective category of many different diseases affecting a variety of organs and tissues in the body. At the cellular level, cancer is characterized by uncontrolled cell growth. Cancer cells appear to have undergone a process of transformation from the normal phenotype to a malignant phenotype capable of autonomous growth (Stephen *et al*., 1989).

Malignant nerve sheath tumor (MPNST) in human beings is an uncommon sarcoma, characterized by schwannian and fibroblastic differentiation (Daimaru *et al*., 1985; Ducatman *et al*., 1986; Enzinger and Weiss, 1998). Rhabdomyosarcoma, Osteosarcoma, Chondrosarcoma, Angiosarcoma, and melanoma are common mesenchymal differentiations; myosarcoma being more common than the others (Ducatman and Scheithauer, 1984; Woodruff and Christensen, 1993; Woodruff, 1976).

MPNSTs account for 26.6% of canine nervous system tumors (Lecouteur, 2001). Supporting cells of the peripheral nerve sheath have the potential for both mesenchymal and epithelial differentiation (Enzinger and Weiss, 1998; Koestner and Higgins, 2002). There were two reports on MPNSTs with divergent differentiation in the veterinary literature, both in dogs, one case with divergent and glandular differentiation (Patnail et al., 1984) and the other with melanotic differentiation (Patnaik et al., 2002). Histologically, PNSTs exhibit two patterns: the Antoni A pattern characterized by dense proliferation of neoplastic cells, and the Antoni B pattern characterized by loose proliferation of neoplastic cells and a prominent

extracellular matrix (Cordy, 1990; Enzinger and Weiss, 1995).

Canine PNSTs most commonly are found unilaterally in the spinal nerves, with the highest frequency in nerves forming the branchial plexus, less in the lumbosacral plexus, and least in subcutaneous sites of distal peripheral nerves. Among the cranial nerves, the trigeminal nerve is most commonly involved. Hemangiosarcoma, leiomyosarcoma, fibrosarcoma, and so on are known as malignant tumors arising from spleen. However, so far, MPNSTs arising from spleen have not been recorded. Here, we report a canine PNST arising from spleen.

2. MATERIALS AND METHODS

The nodules from the liver and spleen of a 14-year-old male cross-breed dog were fixed in 10% buffered formalin and embedded in paraffin. Paraffin-embedded sections were routinely prepared, and stained with hematoxylin and eosin (HE). Immunohistochemical stainings were carried out with the labeled streptavidin-biotin peroxidase technique provided by the kit (Dako, Japan).

For the primary antibodies, rabbit polyclonal antibodies for S-100 protein (Dako); NSE (neuron-specific enolase); NGF (nerve growth factor); SMA (alpha-smooth muscle actin) were used. Diaminobenzidine was used as the chromogen with Mayer hematoxylin counter stain.

3. RESULTS AND DISCUSSION

A 14-year-old male cross-breed dog showed tumefaction in the right hind limb 3 months previously, a loss of appetite, and severe depression. The animal was euthanized because of a poor prognosis.

At necropsy, many yellow-white firm masses at various sizes were found at the liver (Fig. 1a), a well-defined, white firm mass was observed in the spleen (Fig. 1b,c).

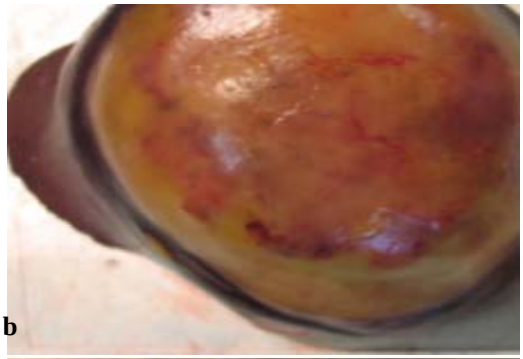

Fig. 1. a) Multiple nodules of various sizes in the liver of dog;
b) A yellow and white, large mass in the spleen of dog;
c) a cut surface of the mass in the spleen.

Histologically, the splenetic tumor consisted predominantly of anaplastic spindle-shaped cells and also confluent areas of heterologous sarcomatous regions with osseous and myxomatous. In the dense cellular areas, spindle-shaped cells were often arranged in interlacing bundles and fascicles with occasional nuclear palisades and whorl formations. The neoplastic cells had spindle to short spindle nuclei with prominent nucleoli and indistinct cell borders. There were two to five mitotic figures per high power field (x40). Only a few collagen fibers were present in the stroma (Fig. 2 a,b).

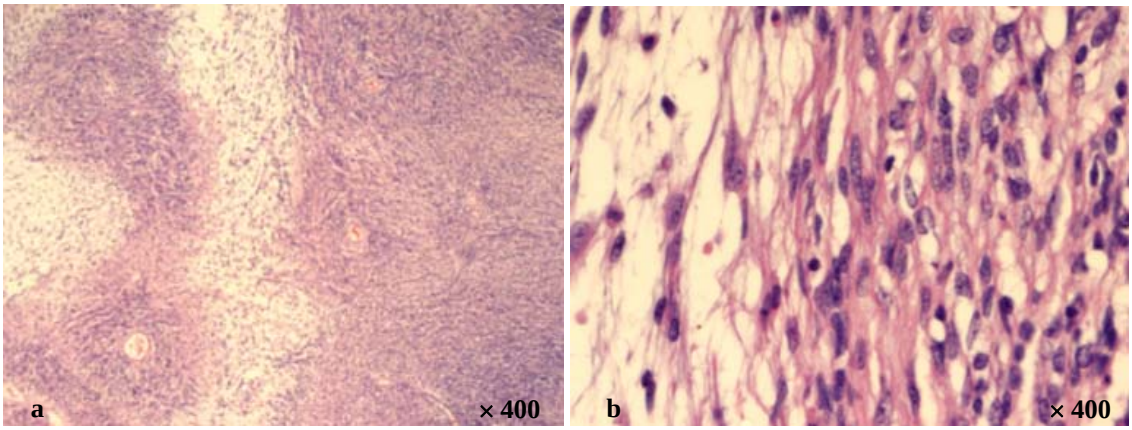

Fig. 2. Splenetic mass. a) Dense proliferation of spindle cells and scattered proliferation of neoplastic cells with mucous stroma are observed. (HE)

b) Palisading is observed. Neoplastic cells have spindle to short spindle nuclei including a prominent nucleolus. Mitotic index is moderate. (HE)

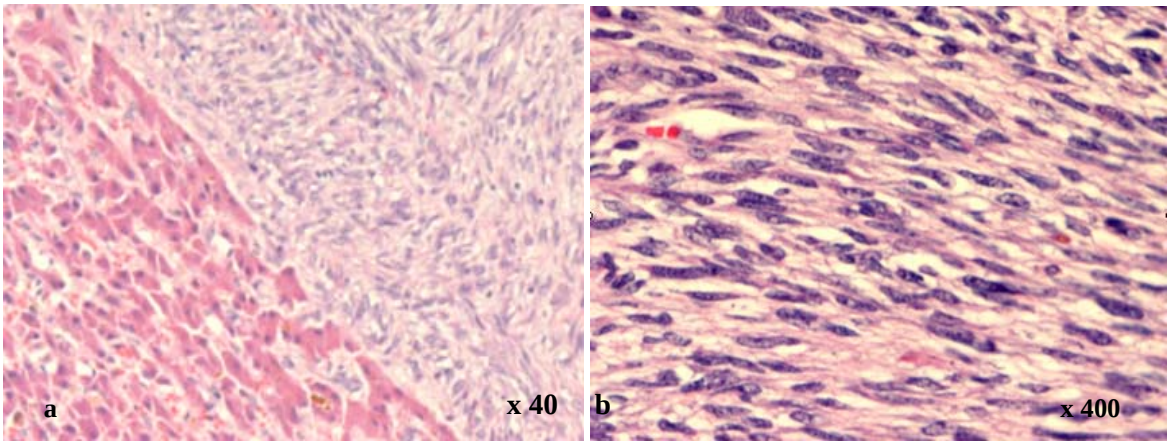

Fig. 3. Hepatic mass. a) Dense proliferation of spindle cells and scattered proliferation of neoplastic cells are observed. (HE)

b) Palisading is observed. Neoplastic cells have spindle to short spindle nuclei including a prominent nucleolus. Mitotic index is moderate. (HE)

The growth pattern and characteristics of neoplastic cells of the hepatic tumors were similar to those of the splenetic tumor (Fig. 3a,b).

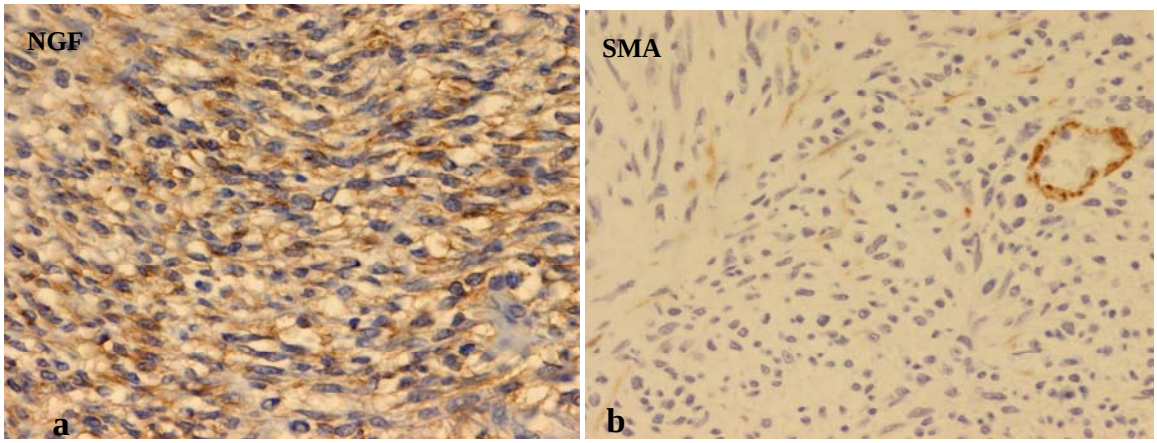

Fig 4. Hepatic mass. Immunohistochemical staining patterns for a) nerve growth factor (NGF) and b) Alpha-smooth muscle. Positive reaction was demonstrated by a brown color. Magnification: x 200. (IHC)

The results of immunohistochemistry were shown in Fig. 4 a,b and Fig. 5 a,b. Tumors were immunohistochemically stained for S-100, NGF, NSE and SMA.

This case, in both spleen and liver, MPNST was observed. Due to the system of blood circulation, the primary lesion maybe came from the spleen and then metastasized to the liver. In the neoplastic mass of spleen and liver, a characteristic histological finding of PNSTs was observed. For example, proliferation of spindle cells, palisades of nuclei, and so on. It has been reported that nerve growth factor receptor (NGFR), expressed in the perineurium of normal peripheral nerves and neoplastic Schwann cells, was demonstrated in human PNSTs (Hosshi et al., 1994; Perosio and Brooks, 1988). The diagnosis of MPNS tumor was based on the results of histopathology and immunohistochemistry. The results of immunohistochemistry indicated that there were proliferations of cells that were positive to SMA in the spleen and liver.

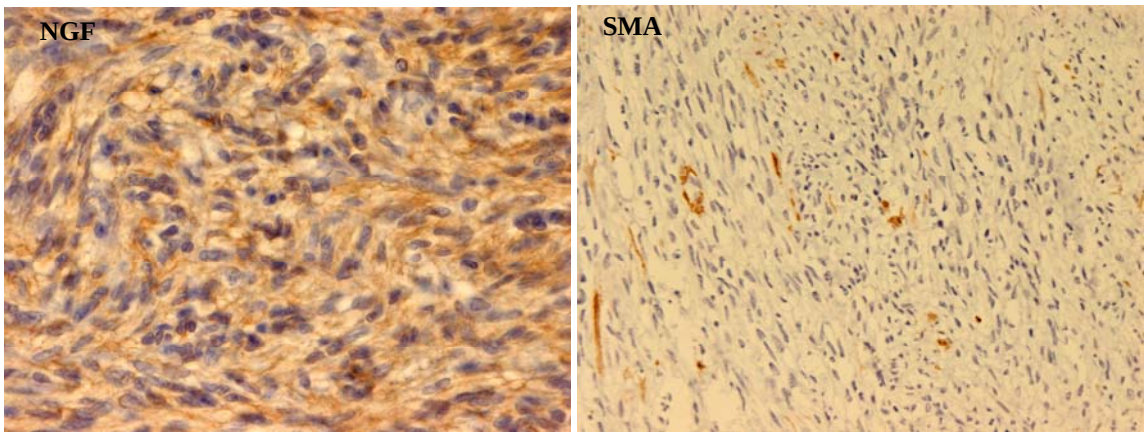

Fig 5. Splenetic mass. Immunohistochemical staining patterns for a) nerve growth factor (NGF) and b) Alpha-smooth muscle. Positive reaction was demonstrated by a brown color. Magnification: x 200. (IHC)

REFERENCES

Cordy, PR. (1990). *In*: Tumors in domestic Animals, 3rd ed. (Moulton, J.B. ed.), Univ. California Press, Berkeley. pp. 640-665.

Daimaru Y, H. Yimoto, M. Enjoyi (1985). Malignant peripheral nerve sheath tumors (malignant schwannomas): an immunohistochemical study of 29 cases. Am J Surg Patho 9: 434-444.

Ducatman B.S., B.W. Scheithauer, D.G. Piepgras, H.M. Reiman, D.M. Ilstrup (1986). Malignant peripheral nerve sheath tumors: a clinicopathologic study of 120 cases. [Cross Ref.] [Medline].Cancer 57: 2006-2021.

Ducatman B.S., B.W. Scheithauer (1984). Malignant peripheral nerve sheath tumors with divergent differentiation. [Cross Ref.] [Medline]. Cancer 54: 1049-1057.

Enzinger F.M., S.W. Weiss (1998). Soft tissue tumors, 3rd ed., CV Mosby, St.Louis, MO.

Enzinger F.M., S.W.Weiss (1998). Soft tissue Tumors, 3rd ed. Pp 821-889, Mosby, St Louis, MO.

Enzinger, F.M., S.W.Weiss (1995). *In*: Soft tissue Tumors, 3rd ed., CV Mosby, St. Louis. pp. 821-928.

Hosshi, N., H. Hiraki, , T.Yamaki, T. Natsume, K. Watanabe, T. Suzuki (1994). Frequent expression of 75 kDa nerve growth factor receptor and phosphotyrosine in human peripheral nerve tumors: an immunohistochemical study on paraffin embedded tissue. Virchows. Arch. 424: 563-568.

Koestner A, R.J. Higgins (2002). Tumors of the nervous system. *In*: Tumors in domestic animals. Ed. Meuten DJ, 5 th ed. Iowa State University press, Ames, IA. pp. 697-738.

Lecouteur R.A. (2001). Tumors of the nervous system. *In*: Small animal clinical oncology. Ed, Withrow SJ and Mac Ewen EG, 3 rd ed. WB Sauders, Philadelphia, PA. pp.521-525.

Patnaik A.K., Erlandson R.A., Lieberman P.H. (1984). Canine malignant melanotic schwannomas: a light and electron microscopic study of two cases. Vet. Pathol 21: 483-488.

Patnaik AK, T.A. Zachos, A.E. Sams (2002). Malignant peripheral nerve sheath tumors with divergent and glandular differentiation in a dog: a case report. Vet. Pathol 39: 406-410.

Perosio, P.M., J.J. Brooks (1988). Expression of nerve growth factor receptor in paraffin embedded soft tissue tumors. Am. J. Pathol. 132: 152-160.

Stephen J. Withow, E. Gregory MacEwen. (1989). Clinical, Veterinary Oncology; J.B. Lippincott Company, Philadelphia, Grand Rapids, New York, St. Louis, San Francisco, London, Sydney, Tokyo.

Woodruff J.M., W.N. Christensen (1993). Glandular peripheral nerve sheath tumor. [Cross Ref.] [Medline]. Cancer 72: 3618-3628.

Woodruff J.M. (1976). Peripheral nerve sheath tumors showing glandular differentiation (glandular Schwannomas). [Cross Ref.] [Medline]. Cancer 37: 2399-2413.